

IJDSDR : Dental PublicationAvailable Online at: www.ijdsdr.com

Volume – 1, Issue – 1, September – October - 2022, Page No. : 01 - 04

Management of mandibular unemployed ridge using a combination of modified impression technique and neutral zone concept: A Case Report¹Azlie Maldusare, Department of Conservative Dentistry and Oral Health, Riga Stradins University, Dzirciema iela 20, Riga 1007, Latvia.²Omgale Slepovakor, School of Dentistry, Universidad, Austral de Chile, Valdivia, Chile.**Correspondence Author:** Azlie Maldusare, Department of Conservative Dentistry and Oral Health, Riga Stradins University, Dzirciema iela 20, Riga 1007, Latvia.**How to Cite This Article:** Azlie Maldusare, Omgale Slepovakor, “Management of mandibular unemployed ridge using a combination of modified impression technique and neutral zone concept: A Case Report”, IJDSDR – September – October - 2022, Vol. – 1, Issue - 1, P. No. 01– 04.**Open Access Article:** This is an Open Access article that uses a funding model which does not charge readers or their institutions for access and distributed under the terms of the Creative Commons Attribution License (<http://creativecommons.org/licenses/by/4.0>) and the Budapest Open Access Initiative (<http://www.budapestopenaccessinitiative.org/read>), which permit unrestricted use, distribution, and reproduction in any medium, provided original work is properly credited.**Type of Publication:** Case Report**Conflicts of Interest:** Nil**Abstract**

Loss of teeth leads to resorption of the edentulous ridges and this phenomenon is seen more in mandibular ridges as compared to maxillary ridges. As the ridge resorption occurs, peripheral part of the denture bearing area gives more support which ultimately leads to fewer loads on the alveolar ridge and the ridge becomes unemployed. The retention and stability of the complete denture is highly compromised in severe unemployed mandibular ridges. Fabrication of complete denture using modified impression technique to record the ridge without putting excess pressure on the ridge and fabricating denture in accordance with the orofacial musculature tends to stabilize the denture. This case report discusses the rehabilitation of the unemployed ridges using a

combination of modified impression technique along with the neutral zone technique.

Keywords: Admix material, External impressions, Neutral zone, Unemployed ridges.**Introduction**

Resorption of the mandibular ridge is a multifactorial process, caused due to various anatomic, hormonal, metabolic, neurological, and mechanical factors. It is a chronic and irreversible process leading to difficulty in the retention and the stability of denture. As the ridge resorption occurs, peripheral part of the denture bearing area gives more support which ultimately leads to fewer loads on the alveolar ridge and the ridge becomes unemployed. The retention and stability of the complete denture is highly compromised in severe unemployed

mandibular ridges. Hence, rehabilitation becomes a challenge to a clinician while fabricating the conventional complete denture. The unemployed ridges should be recorded without putting excess pressure, hence a modification of mucostatic impression technique is utilized. The neutral zone concept is also very crucial in addressing these difficulties. The neutral zone is the area where the outward forces of the tongue are nullified by the inward forces of the lips and cheeks. It is highly effective technique for the fabrication of conventional complete dentures with a severely atrophic ridge. This case report describes a modified impression technique along with the neutral zone technique as well as external impressions for the fabrication of a complete denture for a severely resorbed and unemployed mandibular ridge.

Case Report

A 56-year-old patient reported with the chief complaint of difficulty in eating food due to missing teeth in upper and lower jaw. Intraoral examination revealed completely edentulous upper and lower arches with highly resorbed mandibular ridge (Figure 1A). The mandibular ridge was classified as Order V (low, well-rounded) according to the Atwood's classification. Extraoral examination revealed drooping of commissures and unsupported lips.

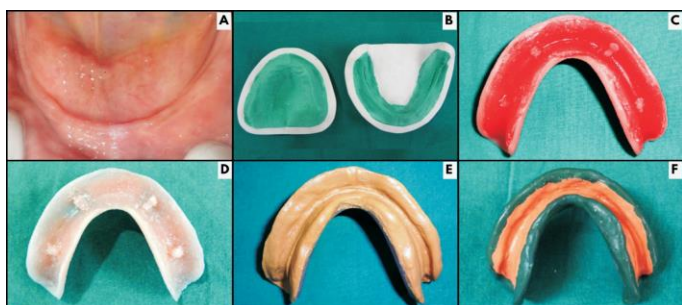


Figure 1: A) Low, well-rounded mandibular edentulous ridge, B) Primary maxillary and mandibular casts, C) Mandibular special tray with wax spacer, D) Autopolymerising resin fabricated special tray after removal of the wax spacer, E) Impression compound as a

spacer material for the mandibular custom tray, F) Border molding using green stick wax for the mandibular arch.

Procedure

Primary impressions were made using the reversible, non-elastic mucocompressive material, impression compound (DPI Pinnacle, Impression Compound) and primary casts were obtained (Figure 1B). A 2mm spacer was adapted and the special trays were fabricated (Figure 1C). The wax spacer was removed (Figure 1D) from the mandibular special tray and perforations were made. The impression compound material was molded and used as a spacer material. The border molding was carried out using green stick (DPI Pinnacle, Tracing Sticks), following which the spacer was removed (Figure 2A). The final impression was made using the light body consistency addition silicone impression material (3M ESPE, Light body consistency Polyvinyl siloxane impression material) (Figure 2B, C). The maxillary (Figure 2D) and mandibular final casts (Figure 2E) were obtained. Occlusal rims were fabricated and the jaw relations were recorded. After the facebow transfer, mounting of the occlusal rims was carried out on the semi-adjustable articulator (Hanau wide Vue articulator) (Figure 3A).

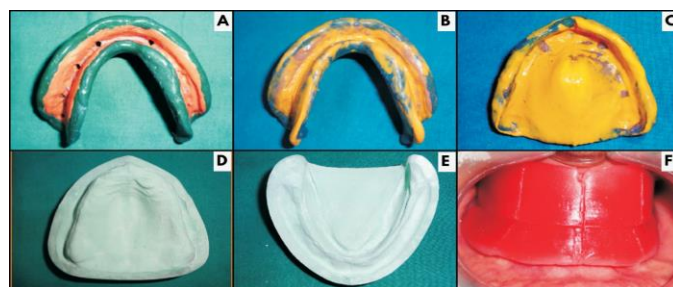


Figure 2: A) Custom tray following removal of the spacer, B) Mandibular final impression, C) Maxillary final impression, D) Maxillary master cast, E) Mandibular master cast, F) Recording the jaw relation.

The mandibular occlusal rim was removed and the admix material (3:7 parts of impression compound and green

stick wax) was adapted on the mandibular temporary denture base. The neutral zone was recorded by asking the patient to carry out various functional movements including pursing the lips, swallowing, sucking, and pronouncing the vowels (Figure 3B). Plaster index was made into three parts, right buccal, left buccal and the lingual (Figure 3C). The teeth arrangement was carried out according to the plaster index and the try-in was done (Figure 3D). The external impressions of the orofacial musculature and the tongue were carried out using the light body consistency addition silicone impression material.

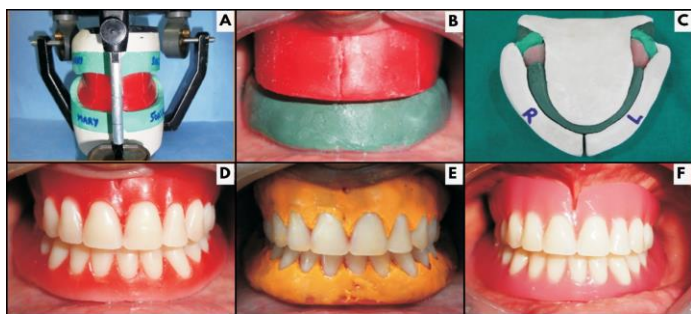


Figure 3: A) Mounting of the occlusal rims on the semi-adjustable articulator, B) Recording of the neutral zone using green stick wax, C) Plaster index adapted around the mandibular rim, D) Try-in of the teeth arrangement, E) External impressions of the maxillary and the mandibular arch, F) Final insertion of the complete denture.

Conventional curing of the denture was carried out and the insertion was done. The patient was satisfied with the results.

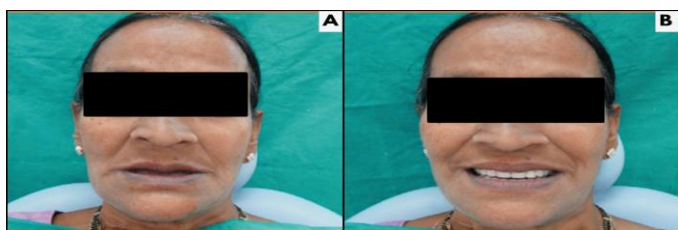


Figure 4: A) Pre-rehabilitative frontal view, B) Post-rehabilitative frontal view.

Discussion

Unemployed ridge poses a great challenge to the clinician, especially the mandibular ridge due to the greater extent of residual ridge resorption. Implant supported prosthesis is a viable treatment option but is not feasible for every patient due to the age, invasiveness, general health conditions, and financial factors. Impression recorded mucostatic over the crest of the ridge and mucocompressive on the peripheral parts, prevents any load being placed on the unemployed part of the ridge. Thus a modified impression technique which recorded the unemployed ridge in mucostatic form gives excellent clinical results. Neutral zone is also an excellent modality in such patients. Various materials have been used in literature for recording the neutral zone including the admix material, waxes, impression plaster, impression compound, tissue conditioners, polyether, and silicone impression material. The impression compound has a high viscosity it is difficult to conduct functional movements. The patient may swallow bits of impression plaster while performing functional movements due to its consistency. The uniform softening of all wax rims is essential for recording full functional movements, and if done incorrectly, might result in inaccurate neutral zone recording. Tissue conditioners lack sufficient body, making them difficult to use even when supported by wire loops. Polyether and silicone impression material sets through an irreversible chemical reaction, making it difficult to modify and reuse the set material.

In this clinical report, admix material was used to record the neutral zone. When a low-fusing compound is combined with an impression compound, a low viscosity admix material is created, allowing for easier manipulation of the oral musculature.

The external impressions following the try-in stage were made using the light body silicone impression material to record the polished surface of the denture in the functional state. This prevents the further accumulation of the food beneath the denture and makes it in harmony with the oral musculature. The fabrication of this complete denture also has added advantages including esthetics, reduced food lodgment, and sufficient tongue space.^[9] Clinicians must identify and record the neuromuscular dynamics of the oral tissues for the fabrication of the prosthesis to be used inside the oral cavity.

Conclusion

Prosthetic rehabilitation of a patient with unemployed edentulous ridges is a difficult task. Modifications to treatment processes should be considered to meet the functional and aesthetic needs of the patient. The denture should be fabricated in harmony with the oral musculature, neutralizing all the inward and the outward forces.

References

1. Faria-Júnior NB, Massi S, Croti HR, et al. Comparative assessment of the flow rate of root canal sealers. *Rev odontociênc* 2010;25(2):170-173.
2. Marciano MA, Guimarães BM, Ordinola-Zapata R, et al. Physical properties and interfacial adaptation of three epoxy resin-based sealers. *J Endod*. 2011;37(10):1417-1421.
3. Silva RV, Silveira FF, Horta MC, et al. Filling Effectiveness and Dentinal Penetration of Endodontic Sealers: A Stereo and Confocal Laser Scanning Microscopy Study. *Braz Dent J*. 2015;26(5):541-546.
4. Weller RN, Tay KC, Garrett LV, et al. Microscopic appearance and apical seal of root canals filled with gutta-percha and ProRoot Endo Sealer after immersion in a phosphate-containing fluid. *IntEndod J*. 2008;41(11):977-986.
5. Ballullaya SV, Vinay V, Thumu J, Devalla S, Bollu IP, Balla S. Stereomicroscopic Dye Leakage Measurement of Six Different Root Canal Sealers. *J Clin Diagn Res*. 2017;11(6):ZC65-ZC68.
6. HuanChen, XinyuanZhao, YuQiu, DengyouXu, LiCui, andBulingWu. The Tubular Penetration Depth and Adaption of Four Sealers: A Scanning Electron Microscopic Study. *BioMed Research International Volume* 2017,1-8.
7. Alalaf NA, Alkhalidi EF. Filling Ability of Various Root canal sealers into simulated lateral canals: An Invitro Study. *Dent Hypotheses* 2022;13:40-4.
8. Manoj SS, Chitre V, Aras M. Management of compromised ridges: A case report. *J Indian Prosthodont Soc*. 2011;11(2):125-9.
9. Chandrasekharan NK, Kunnekel AT, Verma M, Gupta RK. A Technique for Impressing the Severely Resorbed Mandibular Edentulous Ridge. *J Prosthodont*. 2012;21(3):215-8.
10. Silver GK, Love RM, Purton DG. Comparison of two vertical condensation obturation techniques: Touch 'n Heat modified and System B. *IntEndod J*. 1999;32(4):287-295.